

# What is the Diagnosis?

## CASE PRESENTATION

### Irregular tachycardia in young patient

A 17-year-old female with a history of recurrent episodes of palpitation was referred for an electrophysiological study (EPS). She had no other diseases. Transthoracic echocardiogram was completely normal.

The EP study was performed under deep sedation. Two diagnostic catheters were inserted in cardiac chambers by femoral vein access. Baseline measurements were normal (basic cycle length, CL = 870 ms, PA = 15 ms, A-H = 96 ms and H-V = 40 ms), as can be seen in Fig. 1a. There was no VA conduction when RV apex was paced at a CL 50 ms and 100 ms faster than the basal heart rate. Wenckebach cycle (WC) of the atrioventricular node (AVN) was determined by incremental right atrial (RA) pacing through the CS catheter and it occurred at a pacing CL of 360 ms. Programmed stimulation in the RA (trains of 8 stimuli followed by the introduction of a single premature, decrementally, at 10 ms intervals) revealed a discontinuity in the AVN function curve with the presence of two “nodal jumps” (Fig. 1b). The echo zone begun at a BCL: 600 ms – S2: 410 ms, and the tachycardia zone begun at a BCL: 600 ms – S2: 380 ms. Using this stimulation protocol, a narrow QRS tachycardia was reproducibly induced with regularly irregular, alternating, R–R intervals (470–410 ms) (Fig. 2). What is the mechanism of tachycardia and irregularity?

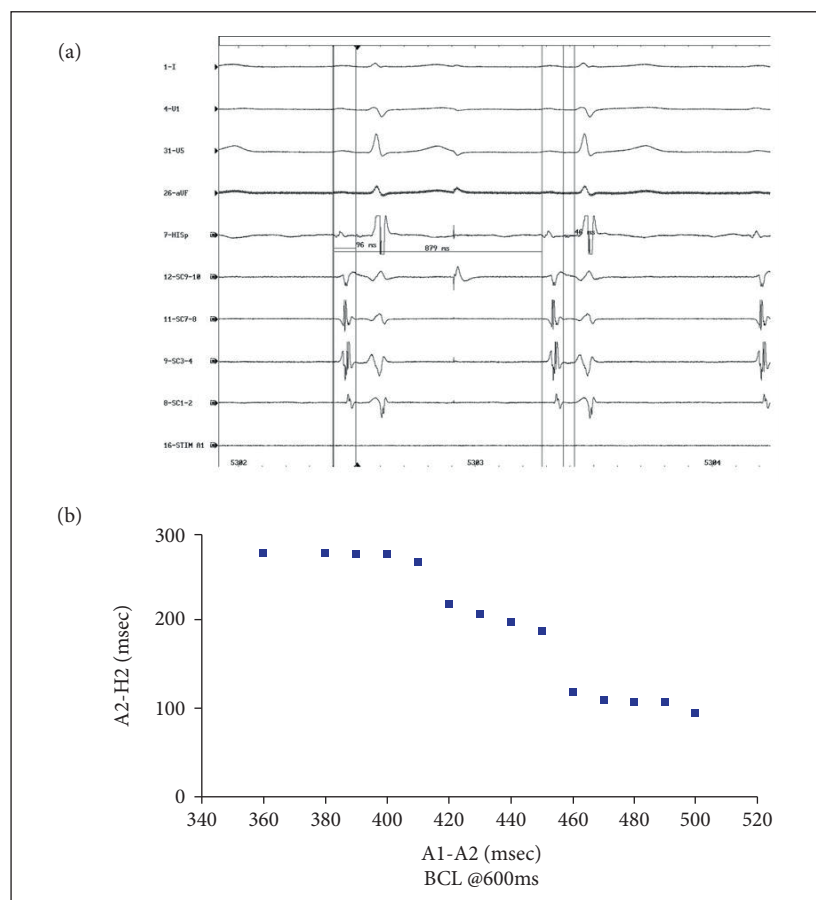


Figure 1. Baseline intracardiac intervals (a) and discontinuity in the AVN function curve (b).ess and palpitation.

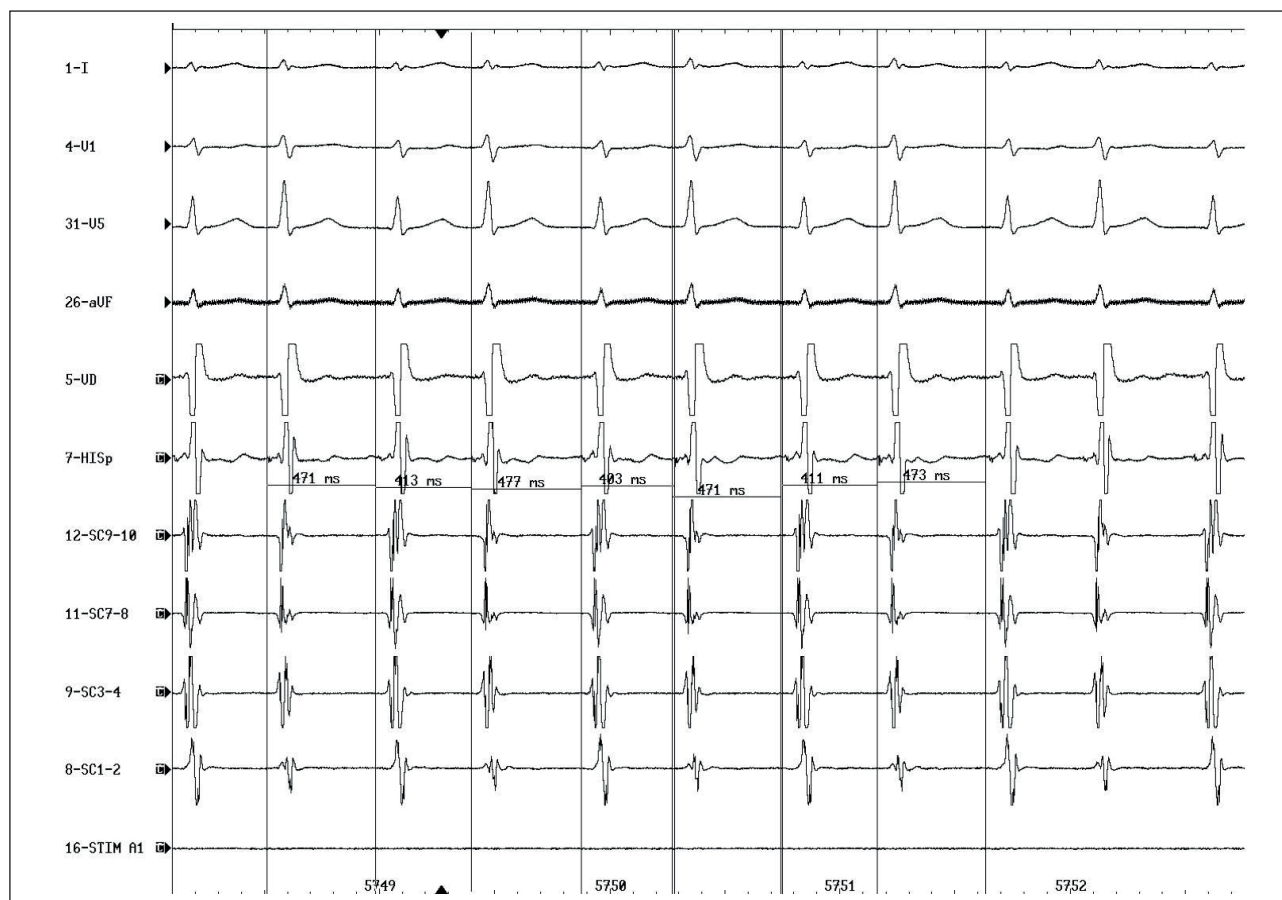


Figure 2. Irregular narrow QRS complex tachycardia. Note two constantly, alternating, H-H intervals.

## ANSWER

The diagnostic probabilities of a narrow QRS tachycardia with a short VA interval and a septal atrial activation are as follows:

1. Atrioventricular nodal reentrant tachycardia (AVNRT);
2. Atrioventricular reentrant tachycardia (AVRT) using a septal by-pass tract;
3. Atrial tachycardia (AT) originating in the septum with a first-degree AV block, and
4. Junctional tachycardia (JT).

The arrhythmia always started with a critical A-H prolongation. It also showed a concentric retrograde atrial activation, and a short VA interval with fixed H-A (A on the His catheter) interval of 20 ms. When there was spontaneous termination of the tachycardia last event was always an A. Entrainment maneuvers were performed by pacing the RV 30 ms faster than the shortest tachycardia CL; during this maneuver, the paced V-A was longer than during the SVT. The response after RV pacing cessation, without termination of the arrhythmia, was a "VAV" type with a PPI-TCL > 115 ms in the RV channel. The additional delivery of PVCs on the refractory His, during the long and short intervals, did not reset the tachycardia. The tachycardia was also managed to terminate reproducibly by carotid sinus massage or adenosine infusion.

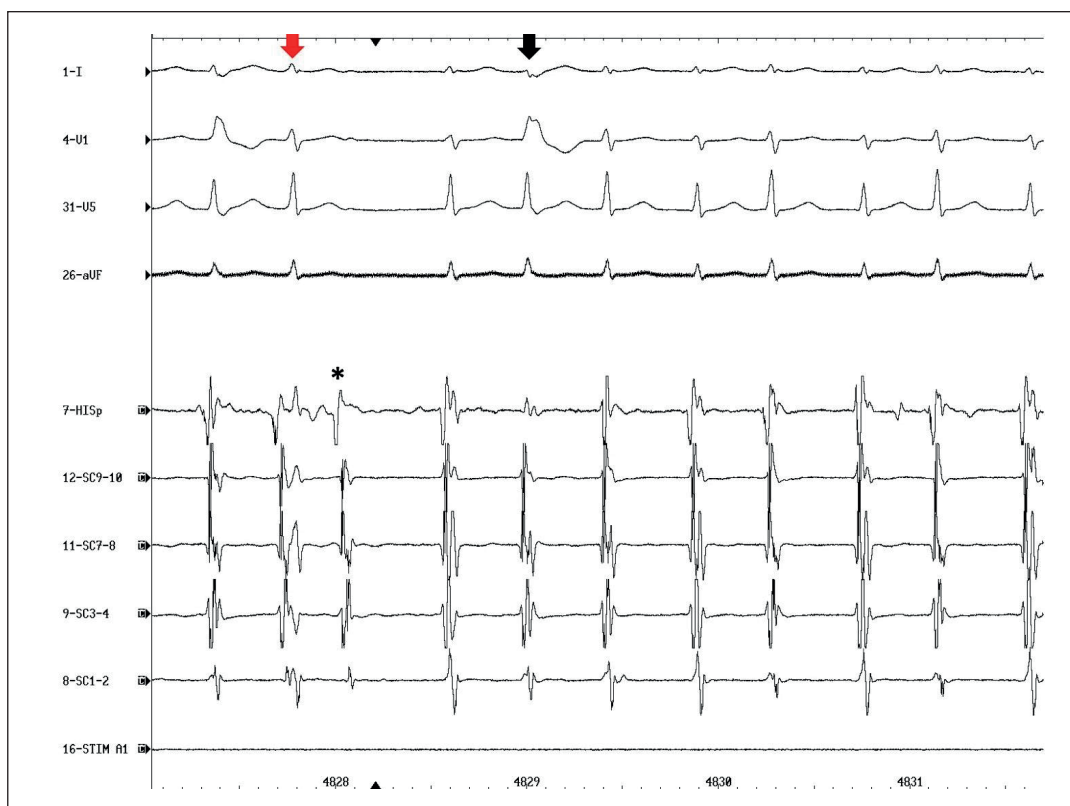During tachycardia, the occurrence of a "bump"-induced RBBB (by the His catheter) did not increase the TCL (when the RBBB occurred in the short interval) ruling out a right sided AP less likely (Figs. 3 and 4). Also,

the absence of a basal VA conduction and the use the described maneuvers rule out the presence of an accessory by-pass tract. The ability to initiate the arrhythmia in a reproductive manner with programmed stimulation made the possibility of an automatic AT or JT less probable.

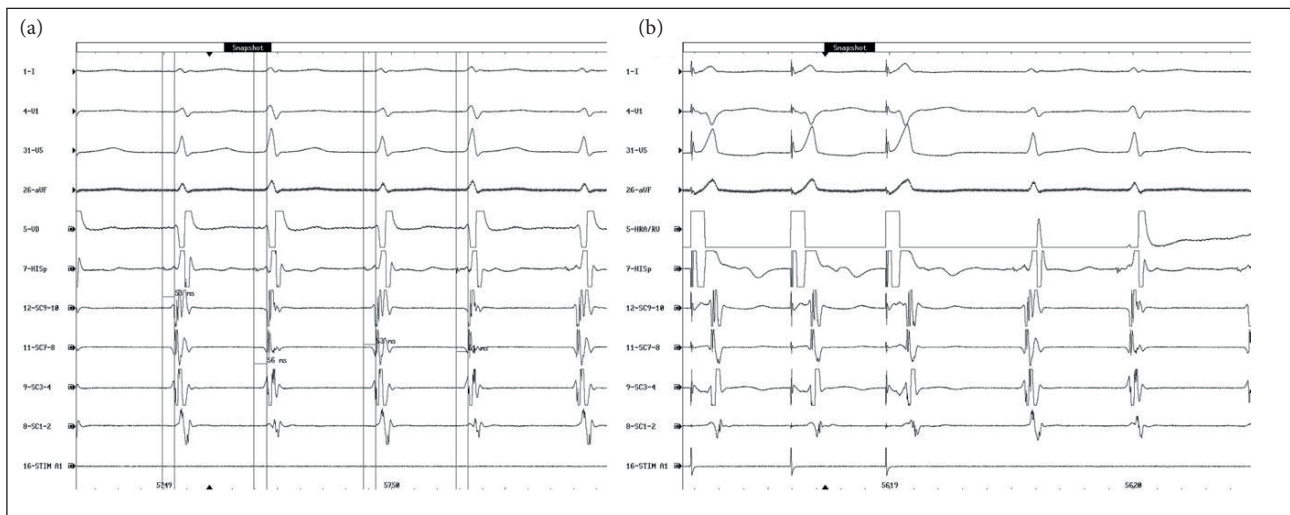
The fact that tachycardia ended spontaneously with the last event being an A also made the probability of an AT less probable; and, also, if it was a JT, it would probably conduct to the ventricle. The very short H–A interval during tachycardia and also the absence of a V–A conduction at baseline made the diagnosis of AVRT also improbable. The analysis of all these findings made AVNRT the most probable diagnosis. An ablation catheter was placed at the base of the Koch’s triangle and radiofrequency was applied eliminating the ability to induce the tachycardia, even after Isuprel infusion.

The AVNRT cycle length usually oscillate due to changes in the anterograde conduction of the slow pathway. Sometimes the same pathway also has alternating conduction velocities due to autonomic modulation or more than one slow pathway being used in tachycardia.

In this case, the fixed variation in the tachycardia CL was probably due to alternating anterograde conduction through two distinct slow pathways with different electrophysiological properties. The presence of dual AV nodal “jumps” and the fixed variation in the TCL suggest the presence of more than one slow pathway involved in the tachycardia. Multiple anterograde AV node pathways are not rare in patients with AVNRT1. However, not all anterograde slow pathways were involved in the initiation and maintenance of tachycardia. Sometimes the presence of more than one pathway with anterograde conduction can mislead the diagnosis of the SVT by the ECG analysis2. In this case, the presence of two slow pathways conducting alternately during tachycardia is the most probable mechanism that explains the beat-to-beat variation of the TCL.



**Figure 3.** Spontaneous termination of supraventricular tachycardia (second QRS complex – red arrow) and reinduction with an atrial beat (\*) that conducts with a prolonged A–H and a nodal echo before the beginning of the arrhythmia. The second tachycardia beat is conducted with a RBBB (black arrow), which may occur due to a mechanical bump or the previous short-long sequence, but the RBBB does not increase the VA interval.



**Figure 4.** Fixed HA interval during tachycardia (a) and V-A-V response upon cessation of ventricular pacing for tachycardia entrainment of tachycardia (b). Note that the V-A interval during ventricular pacing is longer than the one during tachycardia.

## REFERENCES

1. Tai C-T, Chen S-A, Chiang C-E, Lee S-H, Chiou C-W, Ueng K-C, et al. Multiple anterograde atrioventricular node pathways in patients with atrioventricular node reentrant tachycardia. *J Am Coll Cardiol.* 1996;28(3):725-31. [https://doi.org/10.1016/0735-1097\(96\)00217-3](https://doi.org/10.1016/0735-1097(96)00217-3)
2. Richter S, Berrueto A, Mont L, Boussy T, Sarkozy A, Brugada P, et al. Pseudo-atrial fibrillation, rare manifestation of multiple anterograde atrioventricular nodal pathways. *Am J Cardiol.* 2007;100(1):154-6. <https://doi.org/10.1016/j.amjcard.2007.02.067>

## AUTHORS

Tiago Luiz Luz Leiria<sup>1,\*</sup>, Leonardo Martins Pires<sup>1</sup>, Marcelo Lappa Kruse<sup>1</sup>, Gustavo Glotz de Lima<sup>1</sup>

Leiria TLL  <https://orcid.org/0000-0002-3905-102X>

Pires LM  <https://orcid.org/0000-0001-8003-8081>

Kruse ML  <https://orcid.org/0000-0002-2429-4491>

Lima GG  <https://orcid.org/0000-0003-0097-5206>

1. Instituto de Cardiologia do Rio Grande do Sul – Departamento de Eletrofisiologia – Porto Alegre (RS), Brazil.

\*Correspondence author: [tiagoleiria@yahoo.com](mailto:tiagoleiria@yahoo.com)